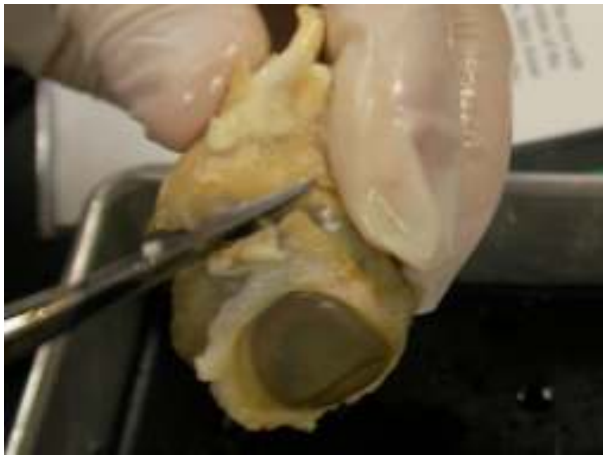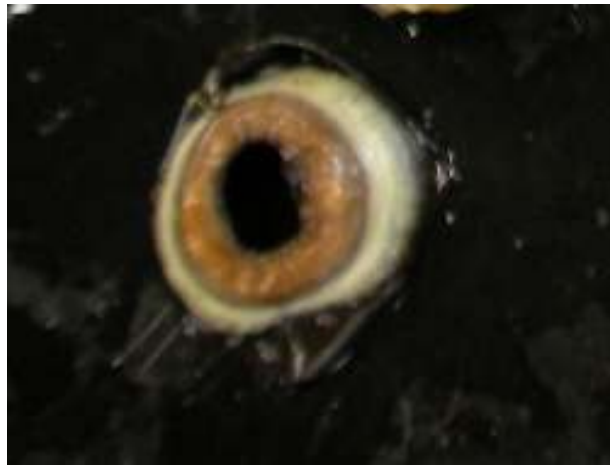


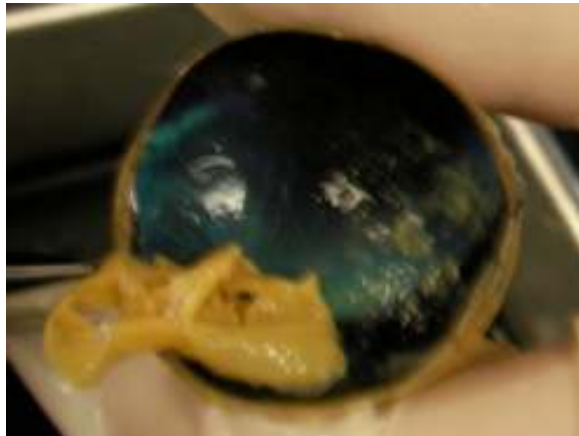
Initial Cut



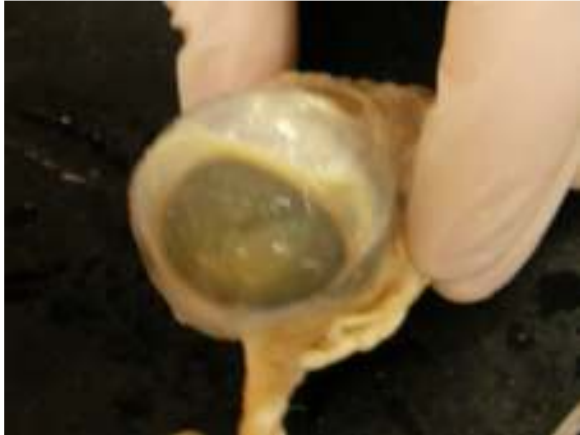Iris & Ciliated body



Lens



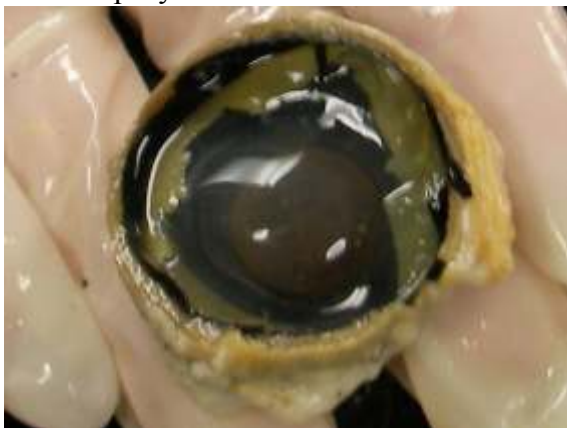Retina, Choroid, and Sclera



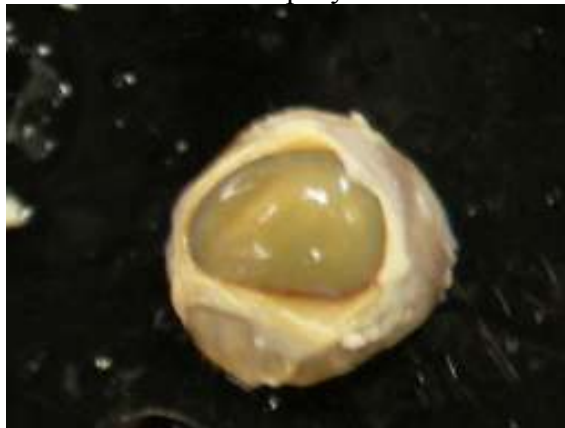Sheep Eye



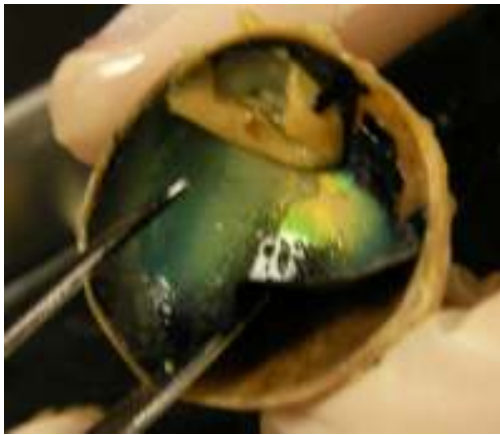Trimmed Sheep Eye



Vitreous Humor sac



Cornea, conjunctiva and sclera



Choroid (thin pigmented layer



Vitreous humor sac